

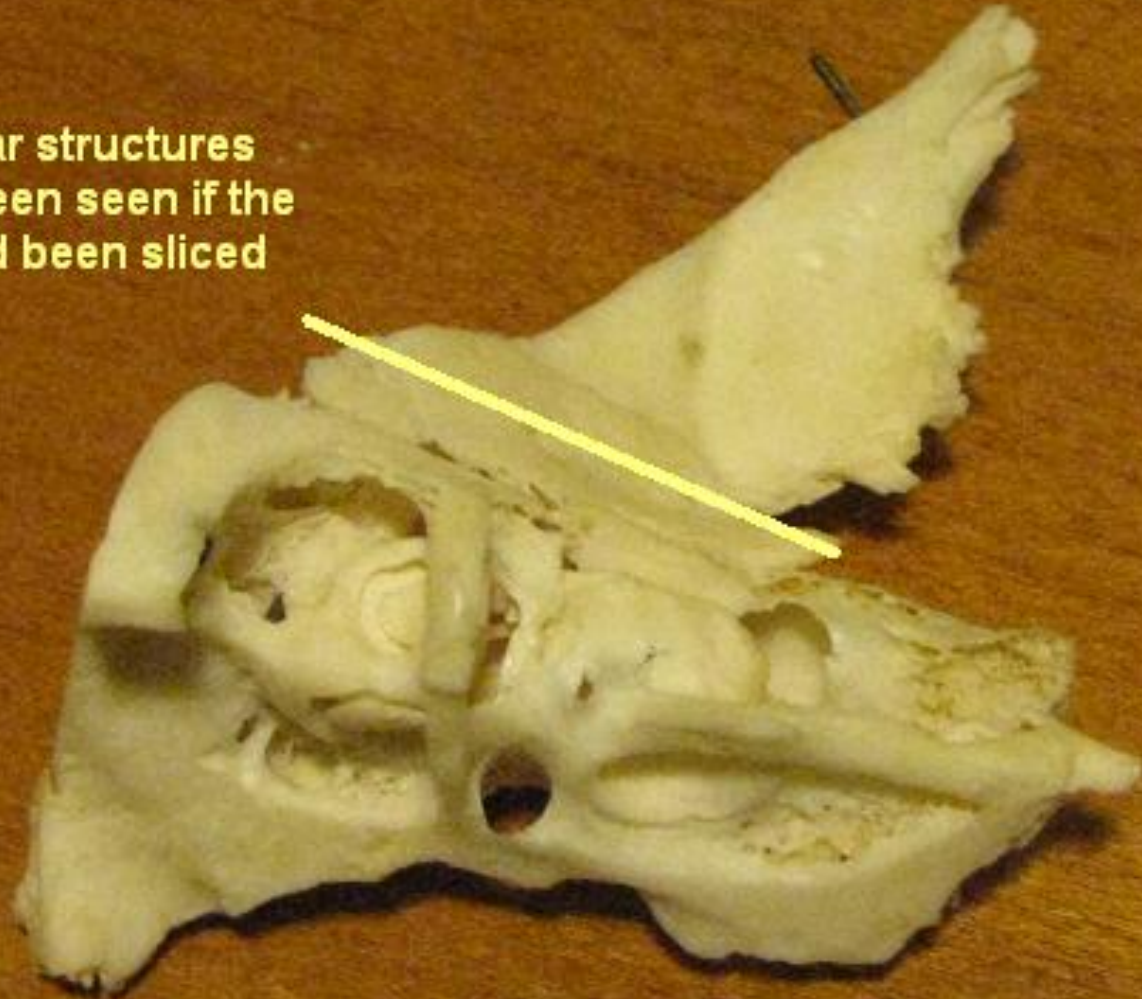
Inner Ear Structures

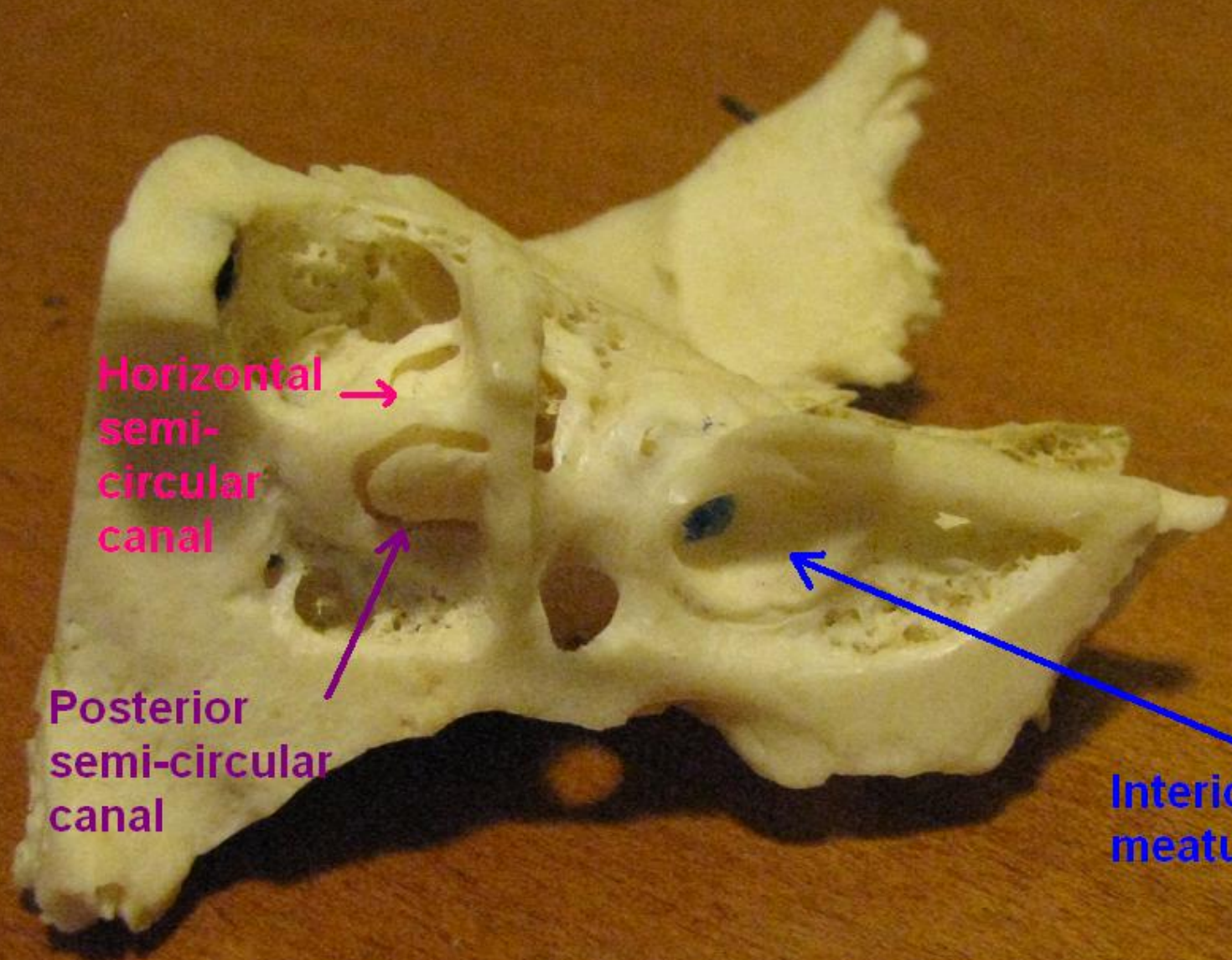
Temporal bone donated by
Dr Chuck Berlin

Photos by Teri Hamill, PhD
Nova Southeastern University

Left Temporal Bone

The middle ear structures could have been seen if the specimen had been sliced about here





Horizontal
semi-
circular
canal

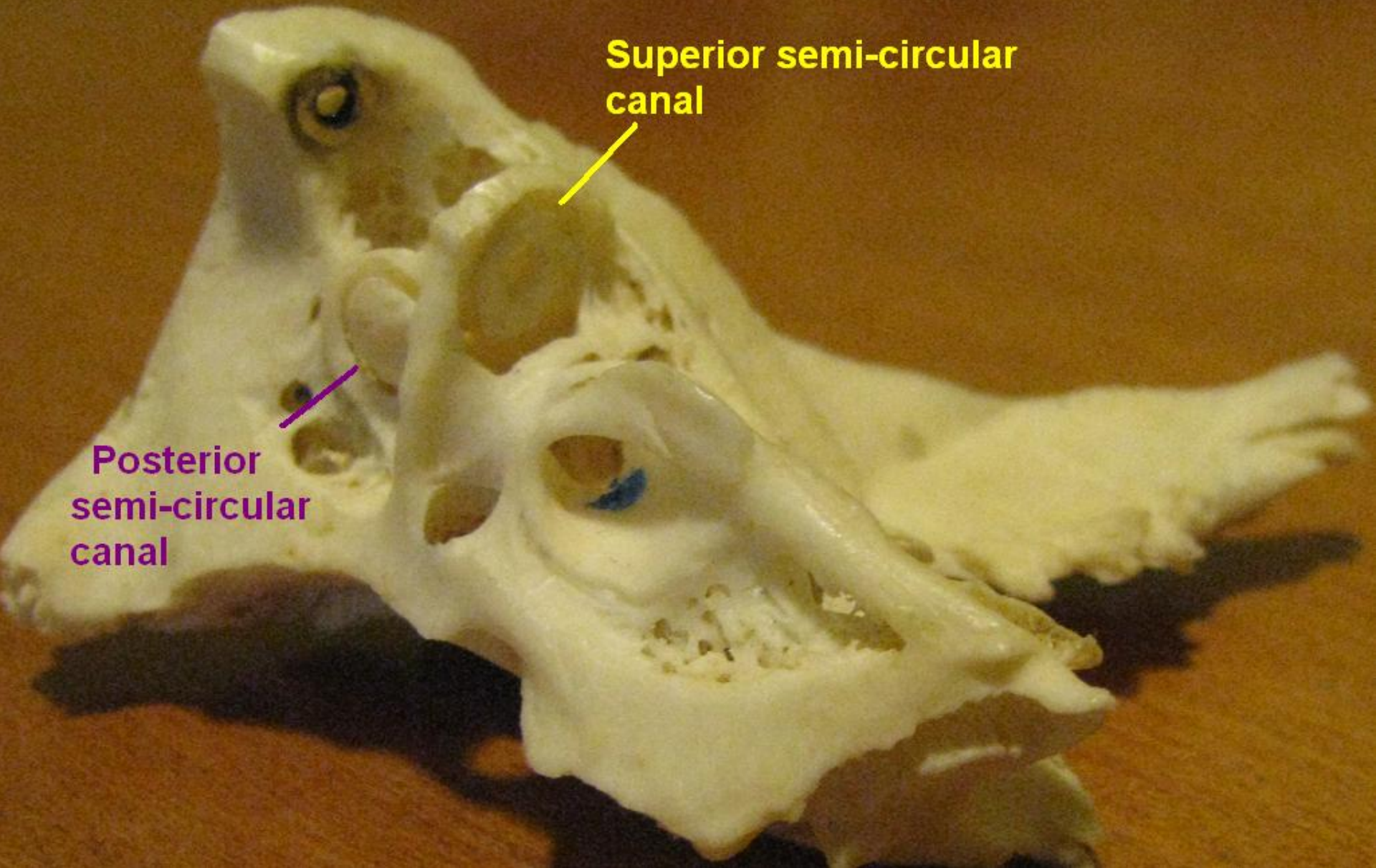
Posterior
semi-circular
canal

Interior auditory
meatus

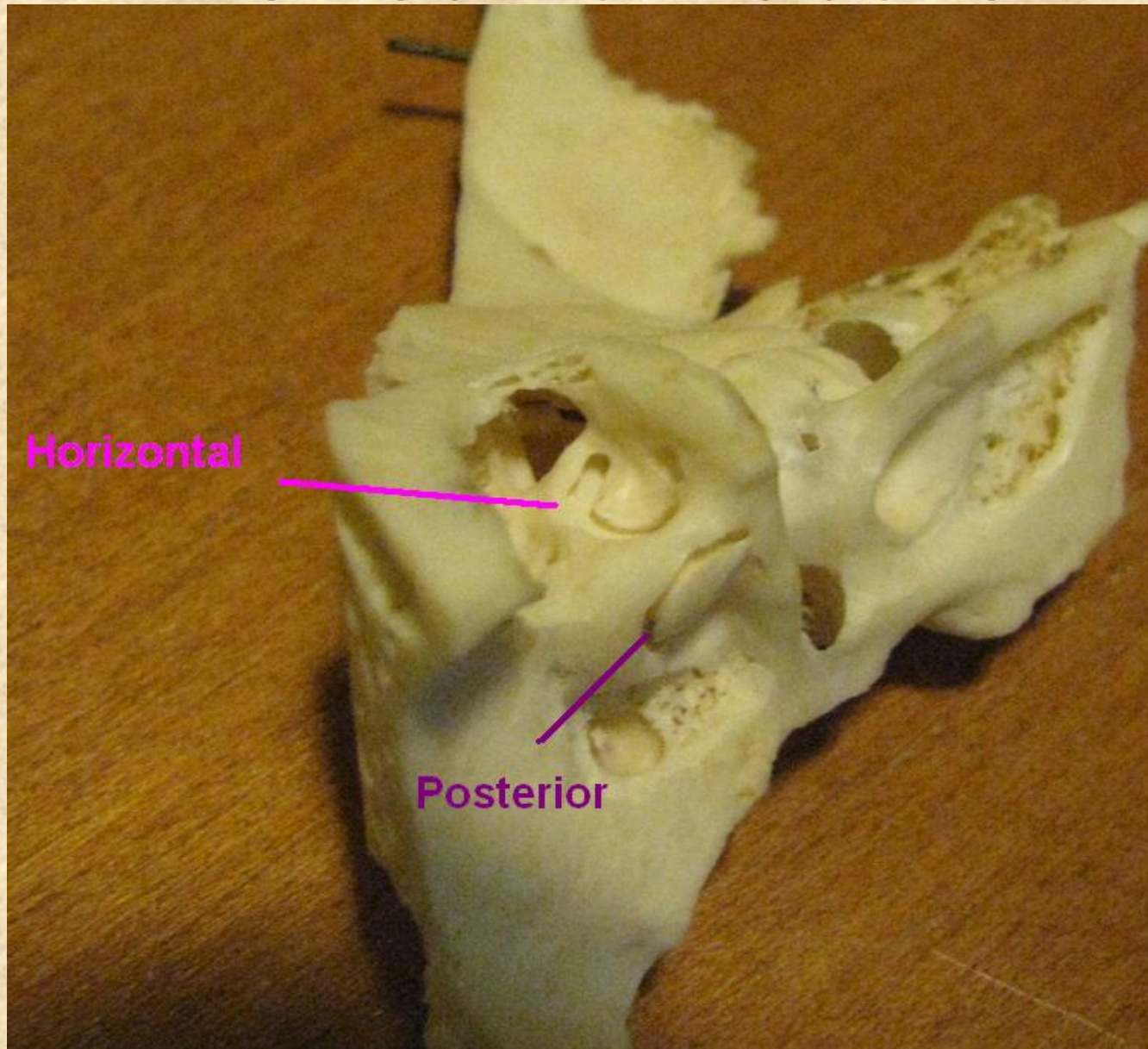
Superior semi-circular canal

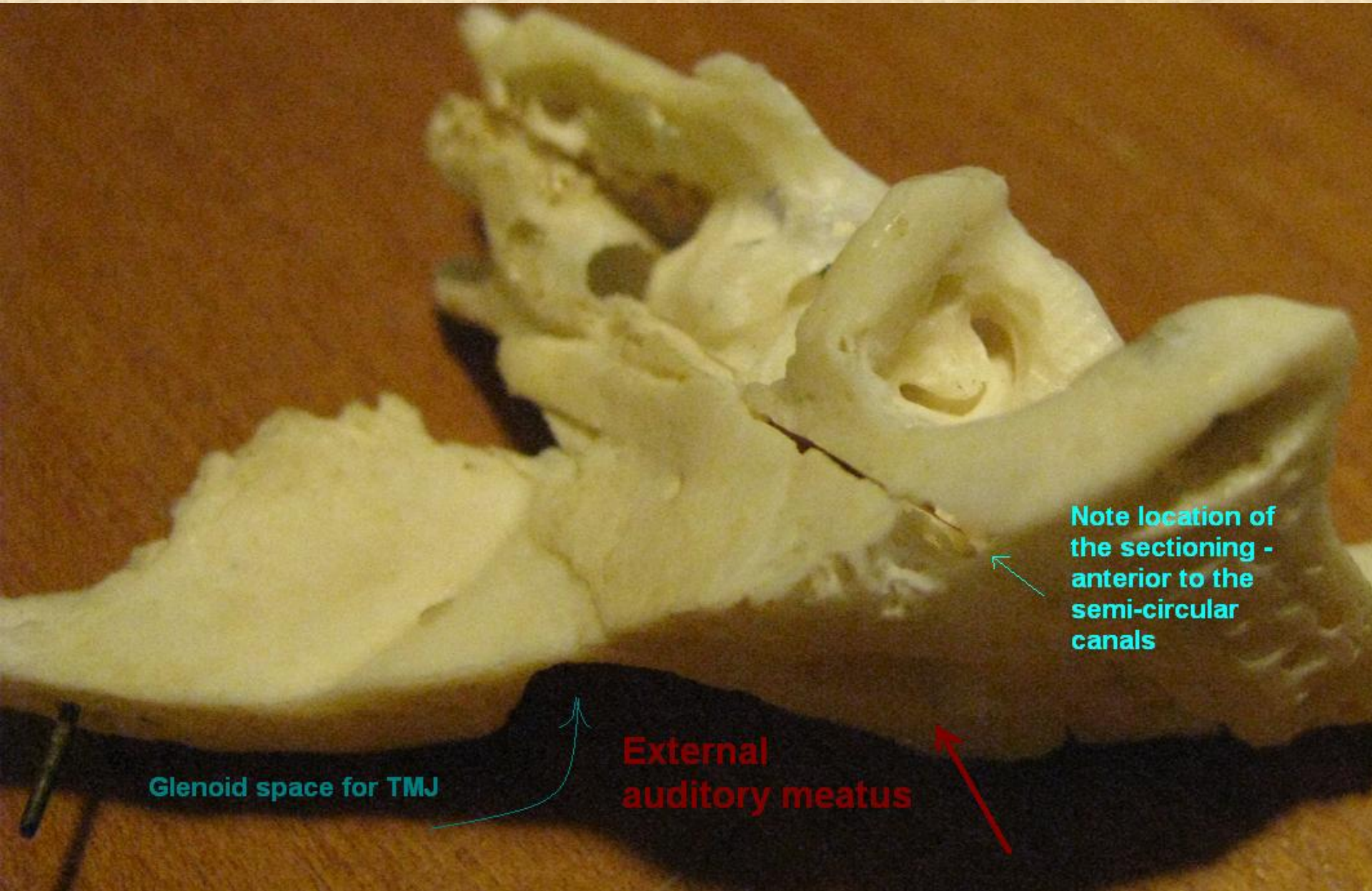


Posterior semi-circular canal



Viewed from above

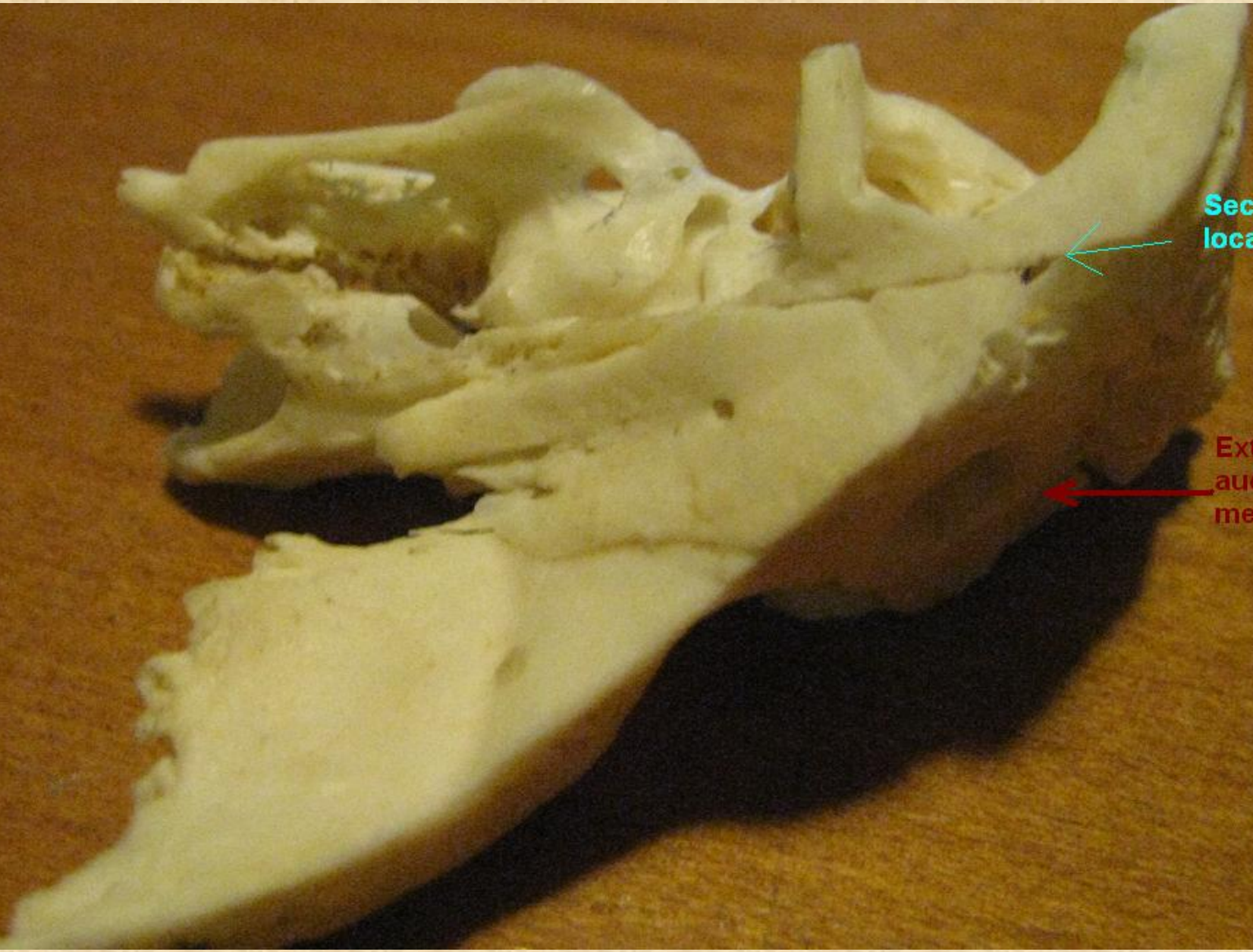




Glenoid space for TMJ

External auditory meatus

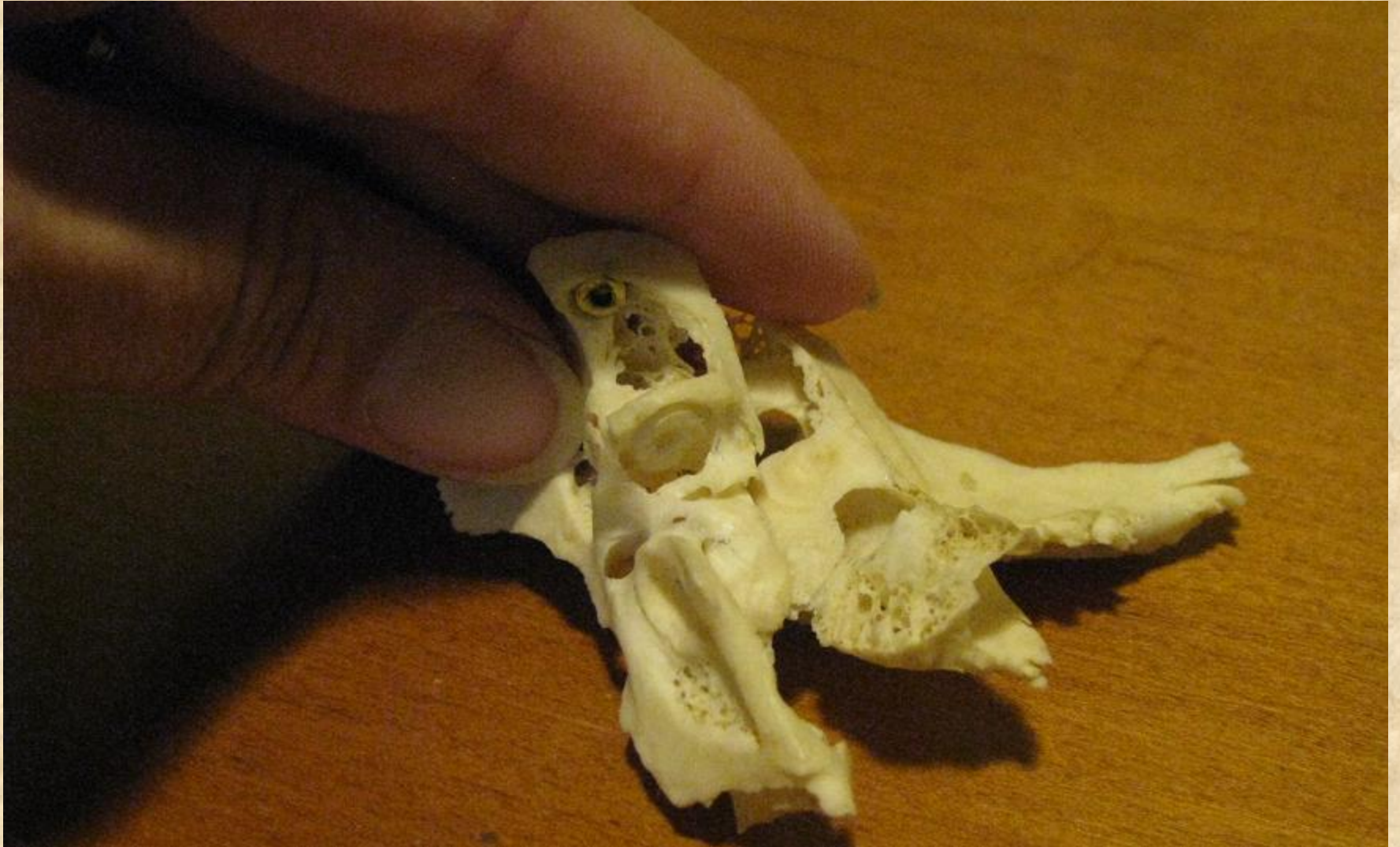Note location of the sectioning - anterior to the semi-circular canals



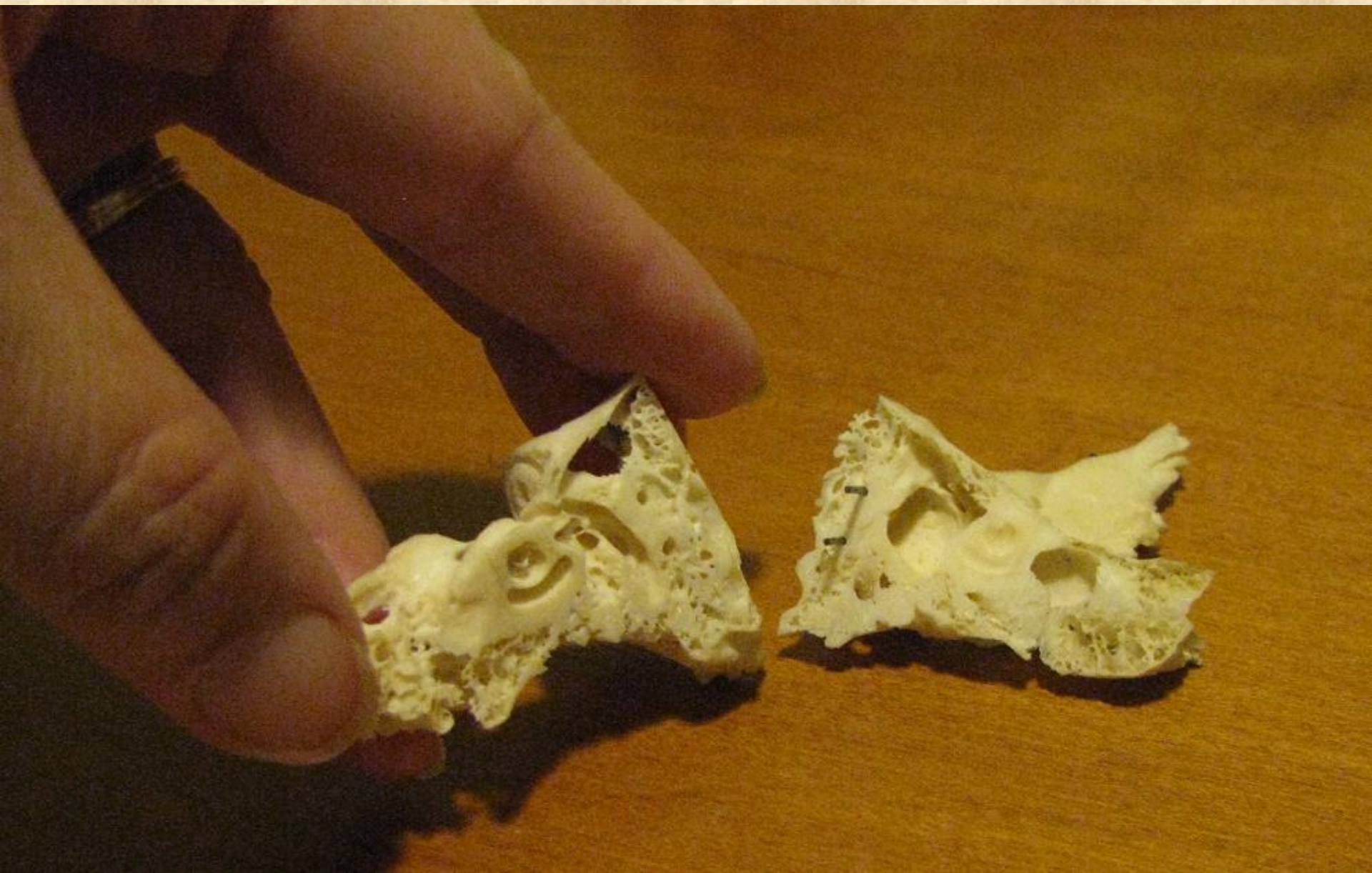
Sectioning location


External auditory meatus

Note size scale



Opening Specimen at Section Line





Cochlea

Middle Ear Space

**Sulcus
for the
tympanic
membrane**

